

Efficacy of Sambiloto Extracts, *Andrographis paniculate*, (Burm. F) in Inhibiting Diabetic Retinopathy Progression: An *in Vivo* Study

Ramzi Amin*¹, Muhammad Apriliandy Shariff²,
Petty Purwanita¹, Mgs Irsan Saleh³

Abstract

Background: Diabetic retinopathy (DR) is one of diabetes mellitus complication and occurred in retinal microvascular. This study was aimed to investigate the efficacy of Sambiloto, *Andrographis paniculate* (*A. paniculata*) extract on glycemic profile, antioxidant and inflammatory cytokine parameters in diabetic rats, and phytochemical analysis of *A. paniculata*.

Methods: *A. paniculata* extract (APE) was carried out by maceration with ethanol. Diabetes mellitus in Wistar male rats was induced with streptozotocin. Retinal vessel diameters were estimated using a method by Vucetic. Inflammatory cytokine and antioxidant parameters were evaluated in retinal tissue. The alkaloid and flavonoid contents in extract were analyzed using thin layer chromatography method.

Results: Funduscopic examination presented some changes in the diameter of the blood vessels. The vessel diameter in the diabetic retinopathy group with APE in concentration of 100 and 200 mg/kg BW groups was significantly lower than in the DR group ($p < 0.05$). The administration of APE in dosages of 100 and 200 mg/kg BW showed reduced glutathione, SOD, and catalase levels compared to the DR group ($p < 0.05$).

Conclusions: *A. paniculata* extract doses of 100 and 200 mg/kg BW improved diabetic retinopathy in rats through hypoglycemic effects, antioxidant effects, and anti-inflammatory mechanisms.

Keywords: *Andrographis paniculata*, Antioxidants, Diabetic Retinopathy, Plant Extracts, Retinal Vessels.

Introduction

Diabetic retinopathy (DR) is a disease that occurs in the retinal microvascular and is one of the most common causes of blindness worldwide (1,2). Diabetes mellitus induces increased oxidative stress and take the role of its complications (3). Oxidative stress produces a series of reactive oxygen species (ROS), which trigger the activation of proinflammatory mediators' cascades such as vascular endothelial growth factor (VEGF) and tumor necrosis factor (TNF- α) (3). These mediators activate the adhesion molecules

upregulation of endothelial and white blood cells (4). Furthermore, leukostasis causes vessel occlusion, ischemia, edema, neuronal function loss, and cell necrotic. Early histological changes in diabetic retinopathy are found in selective loss of pericytes, capillary basement membrane inspissation, increased permeability, and microaneurysms formation. Microvascular occlusion, neovascularization, and neurodegeneration follow these structural and functional changes (4).

Vegetations and herbs have been used as a

1: Department of Ophthalmology, Faculty of Medicine, Universitas Sriwijaya/Dr Moh Hoesin General Hospital, Palembang, Indonesia.

2: Specialized Residency Training, Faculty of Medicine, Universitas Sriwijaya/Dr Moh Hoesin General Hospital, Palembang, Indonesia.

3: Department of Pharmacology, Faculty of Medicine, Universitas Sriwijaya, Palembang, Indonesia.

*Corresponding author: Ramzi Amin; Tel: +62 81949581088; Email: ramziamin@fk.unsri.ac.id.

Received: 15 May, 2022; Accepted: 25 May, 2022

source of traditional medication, and many researches have classified plants as an excellent source of new therapies for many severe diseases (5-7). Vegetations with antidiabetic ability are believed to be treasured sources for novel oral antidiabetic therapy. *Andrographis paniculata* (Burm. F.) or commonly known as Sambiloto in Indonesia is a potential source of antidiabetic compounds (6). *Andrographis paniculata* (AP), originating from India, is widely spread in Southeast Asia, including Indonesia, and is often used as herbal drink and therapy for various disorders such as tonsillitis, fever, diabetes mellitus, skin rash, and colds. In several studies, *A. paniculata* extract (APE) has been shown to lower blood glucose levels in diabetic rats (6,8). This vegetation is a shrub with a high flavonoid component, where flavonoids are powerful antioxidants. Antioxidants are compounds that have the potential to overcome oxidative stress process in cells where the AGEs Advanced Glycation End Products (AGEs) accumulation in cells and tissues takes part in the initiation of oxidative stress in cells and tissues (8). Oxidative stress constrains the inflammatory cascade and inhibits necrosis and apoptosis in cells and tissue. This study is the first study that pointedly explores the effect of APE in inhibiting the progression of diabetic retinopathy *in vivo* in the rat model of diabetic retinopathy.

Materials and Methods

Animals

Thirty Wistar male rats (*Rattus norvegicus*) (220-250 g) were obtained from the Eureka Research Laboratory and Experimental Animal Breeding Co., Ltd (Palembang, Indonesia). All animals were placed in polypropylene cages under measured conditions of 12 hours of the light-dark cycle, temperature 22 ± 1 °C and humidity 40-60% in the registered animal house (905/ELR/2021) at Eureka Research Laboratory, Palembang, Indonesia. Throughout the treatment, the animals were fed with standard pellet diet (Japfa, Indonesia) and water *ad libitum*.

Experimental procedure

The animals were divided into five groups: normal (control) group, diabetic retinopathy (DR) group, DR+ *A. paniculata* extract (APE) 50 mg/kg BW group, DR+ APE 100 mg/kg BW group and DR+ APE 200 mg/kg BW group. Group DR received an oral suspension without AP extract 1 mL intragastric; treatment groups each received APE suspension 50, 100, and 200 mg/kg BW intragastric. Diabetes mellitus in rats was induced with streptozotocin (STZ, 45 mg/kg BW) (9). Blood glucose levels were evaluated at the starting of diabetes mellitus induction and 24 hours after STZ/vehicle injection. Rats showing blood sugar levels of more than 200 mg/dL were considered diabetes mellitus. After 30 days of treatment, the rats were euthanized by administering a pentobarbital overdose. The eyes were evacuated, and the retina was separated and frosted in liquid nitrogen for laboratory examination.

Andrographis paniculata extract preparation

Andrographis paniculata (AP) leaves were accumulated from Palembang, South Sumatra, Indonesia, in June 2021 and identified by the Department of Botany, Faculty of Science, Universitas Sriwijaya, Palembang, Indonesia. The voucher specimen (No. 2021/78) is kept at the Department of Biology, Faculty of Medicine, Universitas Sriwijaya, Palembang, Indonesia. *Andrographis paniculata* (AP) simplicia was prepared to analyze its hypoglycemic effect and investigate the basic phytochemical compound of the plant. The extract was prepared using 96% ethanol for 72 hours by maceration method. Then the macerate was thickened using a rotary evaporator. All extracts were stored at -4 °C until use. The extract is insoluble in water; the suspension is made for oral application. The weighted amount of the extract was triturated with 0.3% Tween 80, and then 0.25% hydroxyl propyl methylcellulose (HPMC) was added gradually to increase viscosity and make up the final volume.

Fundus photograph and retinal vessel diameter evaluation

Tropicamide (1%) is dropped to enlarge the pupil. The photographs of fundus were taken every week using a Nikon camera (Nikon, Japan) mounted on a slit lamp with 16x magnification plus a 90D lens placed in front of the animal's eyes. A Hydroxyl propyl methylcellulose eye drops (0.7%) were administered repeatedly to hydrate the cornea. Retinal vessel diameters were estimated using a method by Vucetic et al (10). The diameters of the three most prominent veins were assessed at three locations in the most extensive section at the same distance from the center. Before diameter evaluation, all groups' retinal snapshots were chosen randomly, and three independent observers performed the assessment. The mean of three estimates was used as the definite retinal vessel diameter.

Glycemic parameters

Blood glucose was evaluated with the glucose oxidase-peroxidase method using a commercial kit by piercing the distal end of the rat's tail with the Accu-Chek Softclix Lancing Device on an Active Glucose Test Strip (Roche Diagnostics, Chennai, India). Glycosylated hemoglobin (HbA1c) was assessed using an ion exchange resin kit (Biosystems S.A., Barcelona, Spain).

Evaluation of antioxidant parameters

Spectrophotometric examination of reduced glutathione (GSH) was performed by the method of Moron et al. (11). Superoxide dismutase (SOD) activity was evaluated using Misra et al. method (12). One unit of SOD activity was defined as the amount of enzyme needed to form 50% inhibition of adrenaline auto-oxidation. Catalase activity (CAT) was evaluated as stated in Aebi method (13). One CAT unit of activity was described as a nmol of decomposed H₂O₂ per minute/mg protein. Estimates were made in 100 mL retinal homogenate. Protein assessment in every sample was carried out using Lowry et al. method (14). All assessments were carried out in duple.

Inflammatory cytokine parameters

According to the manufacturer's instructions, retinal TNF- α levels were examined using a commercial enzyme-linked immunosorbent assay (ELISA) kit from Diaclone (Diaclone, Besançon, France). According to the manufacturer's instructions, rat retinal VEGF was examined using a commercial ELISA kit (Ray Biotech Inc., Georgia, USA). Estimates were made in 100 mL retinal homogenate. All assessments are performed in duple.

Thin layer chromatography analysis

The extracts were evaluated using standard thin layer chromatography (TLC). The sample was put on a Merck 10 mm \times 10 mm 60 F254 plate containing the solvent system. A commixture containing dichloromethane, 85:MeOH, 14:NH₄OH (25%), 1, was used for the alkaloids, and the plates were visualized using Dragendorff's reagent. For flavonoids, a mixture containing ethyl acetate, 60: formic acid, 10: acetic acid, 10: water, 20 is used. Both plates were visualized using diphenylborinic acid. Twenty ml of a mixture containing ethyl acetate, 6: HE 14, was used for terpenes. The plate was visualized with UV light using vanillin stain (15).

Statistical analysis

All data are presented as mean and standard deviation. Each group was compared with one-way ANOVA followed by a Tukey post-hoc. The comparison between several groups was analyzed using the Kruskal-Wallis test if the data distribution was not normal or homogeneous. The differences between the two groups are analyzed using the Mann-Whitney test. Figures were generated using Adobe Photoshop (Adobe Software, San Diego, CA, United States).

Ethical approval

All experiments in this study complied with the bioethical research established by the Institutional Animal Care and Use Committee, Faculty of Medicine of Universitas Sriwijaya (No. 089-2021); and its methodology

conforms to the published guide “Principle of laboratory animal care” (16).

Results

Glycemic parameters

At the end of the treatment period, blood glucose levels in the diabetes group were significantly greater than in normal rats ($p < 0.05$). In rats given APE 100 and 200 mg/kg BW, blood glucose

levels were significantly decreased than diabetic group ($P < 0.05$) but still more elevated than normal group ($p < 0.05$). Thus, HbA1c level in the diabetic group was more increased than in the normal rats ($p < 0.05$). In APE 100 and 200 mg/kg BW group, HbA1c levels were significantly higher ($p < 0.05$) compared to the normal group but more decreased ($P < 0.05$) than in the diabetes group (Table 1).

Table 1. Effect of *A. paniculata* extract on glyceimic parameters after treatment.

	Body weight (grams) \pm SD	Blood glucose (mg/dL) \pm SD	% HbA1c \pm SD
Normal	299.6 \pm 26.5	98.8 \pm 2.3	4.6 \pm 0.5
Diabetic retinopathy (DR)	279.9 \pm 23.5	599.7 \pm 37.3	8.4 \pm 0.6
DR + APE 50 mg/kgBW	279.2 \pm 25.8 ^a	577.9 \pm 34.9 ^b	7.8 \pm 0.7 ^b
DR + APE 100 mg/kgBW	284.8 \pm 27.6 ^{ab}	379.8 \pm 21.5 ^{ab}	6.9 \pm 0.5 ^{ab}
DR + APE 200 mg/kgBW	291.8 \pm 27.3 ^{ab}	308.6 \pm 21.8 ^{ab}	5.7 \pm 0.7 ^{ab}

^a $p < 0.05$ versus diabetic retinopathy group; ^b $p < 0.05$ versus normal group; APE: *Andrographis paniculata* extract; DR: Diabetic retinopathy; SD: standard deviation.

Fundus photography

Fundoscopic examination presents changes in blood vessels diameter (Fig. 1). The mean retinal blood vessel diameter in the normal and diabetic retinopathy groups were 53.9 \pm 3.7 and 59.2 \pm 3.5 pixels, respectively. In addition, the mean retinal blood vessels in the DR+ APE 50,

100, and 200 mg/kg BW groups were 59.5 \pm 3.4; 56.8 \pm 3.9; and 53.2 \pm 3.8 pixels; respectively. The mean vessel diameter in the DR+APE 100 and 200 mg/kg BW groups was significantly decreased than in the diabetic retinopathy group ($p < 0.05$).

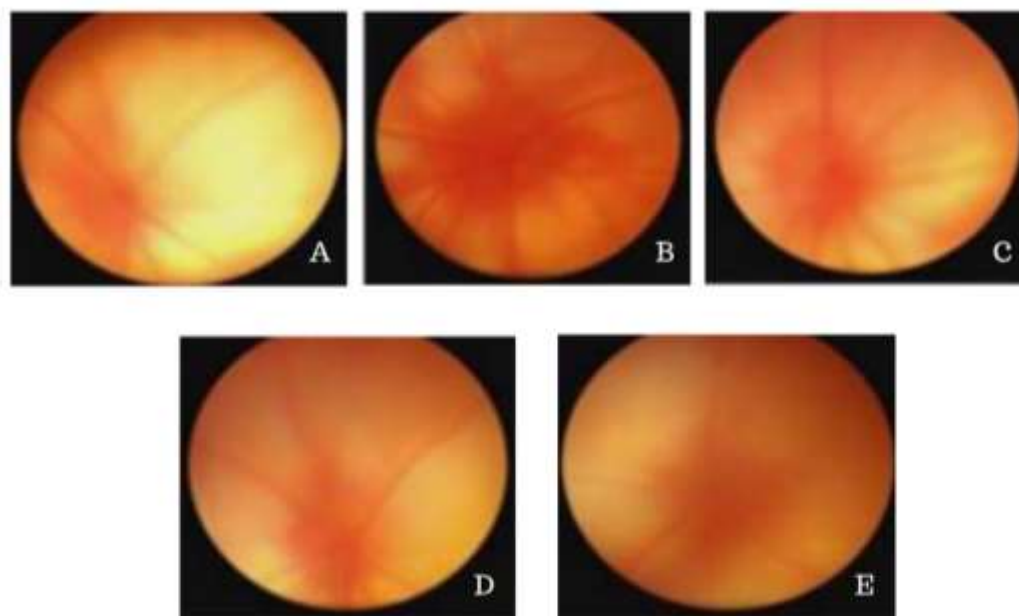


Fig. 1. Fundus photography of rats after treatment; A. normal group; B. diabetic retinopathy (DR) group; C. DR + APE 50 mg/kg BW; D. DR+APE 100 mg/kg BW; E. DR+APE 200 mg/kg BW.

Inflammatory parameters

The DR+APE 100 and 200 mg/kg BW groups showed the ability to significantly reduce TNF- α levels compared to the DR group

($p < 0.05$). Similarly, the administration of APE 100 and 200 mg/kg BW presented the significant ability to reduce VEGF levels compared to the DR group ($p < 0.05$) (Fig. 2).

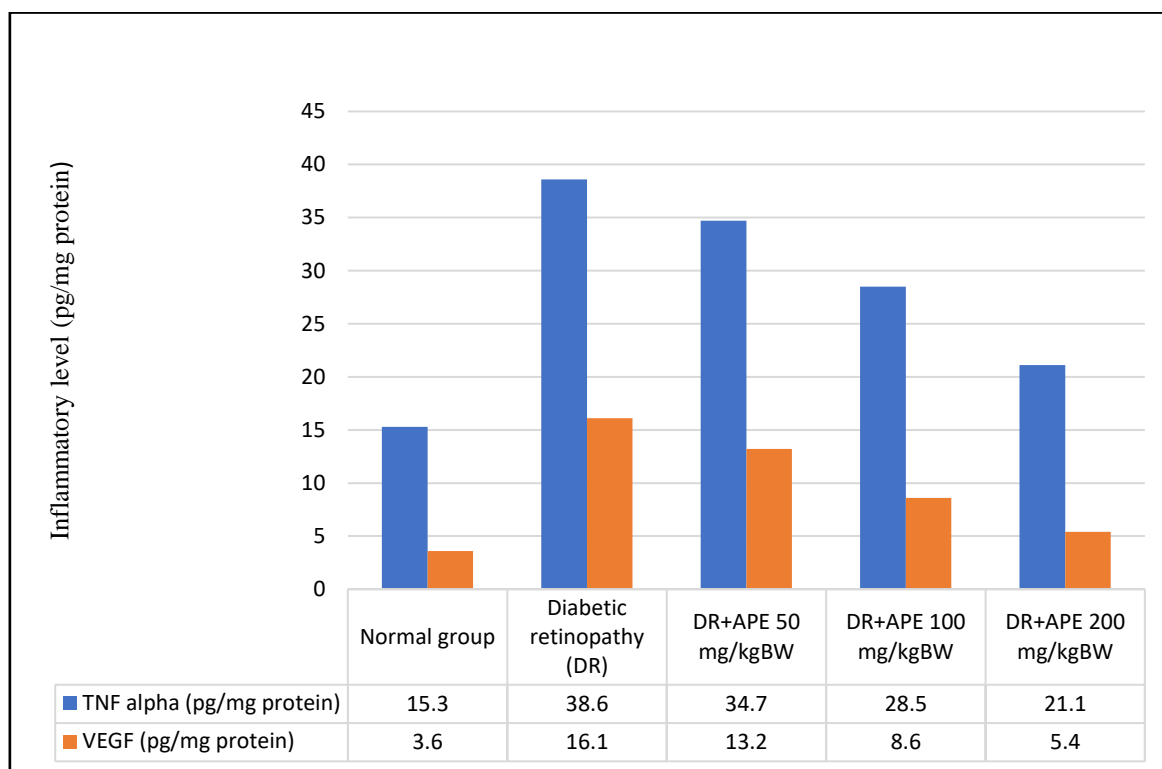


Fig. 2. Inflammatory levels of TNF- α (blue) and VEGF (orange) in rat retinal tissue after treatment. ^a $p < 0.05$ versus diabetic retinopathy group; ^b $p < 0.05$ versus normal group.

Antioxidant parameters

The DR+APE 100 and 200 mg/kg BW groups showed the ability to reduce SOD significantly and catalase levels compared to DR group

($p < 0.05$). The administration of APE 100 and 200 mg/kg BW also revealed the ability in reducing glutathione levels compared to DR group ($p < 0.05$) (Table 2).

Table 2. Effect of APE on antioxidant parameters after treatment.

	SOD (IU/mg protein) \pm SD	Catalase (IU/mg protein) \pm SD	Glutathione (η mol/mg protein) \pm SD
Normal	19.6 \pm 2.5	4.8 \pm 1.3	25.6 \pm 1.5
Diabetic retinopathy (DR)	9.9 \pm 1.5	1.7 \pm 0.3	14.4 \pm 2.6
DR + APE 50 mg/kgBW	10.2 \pm 1.8 ^b	1.9 \pm 0.9 ^b	15.1 \pm 1.7 ^b
DR + APE 100 mg/kgBW	14.8 \pm 1.6 ^{ab}	2.8 \pm 0.5 ^{ab}	18.9 \pm 0.5 ^{ab}
DR + APE 200 mg/kgBW	17.8 \pm 1.3 ^{ab}	3.6 \pm 0.8 ^{ab}	20.7 \pm .7 ^{ab}

^a $p < 0.05$ versus diabetic retinopathy group; ^b $p < 0.05$ versus normal group; APE: *Andrographis paniculata* extract; DR: Diabetic retinopathy; SD: standard deviation.

Phytochemical analysis

The phytochemical analysis result is presented in table 3. It can be seen that the highest

content of APE is flavonoid. Flavonoids are antioxidants that work against ROS formation in the body.

Table 3. Phytochemical test of *A. paniculata* extract

Extract	Alkaloid	Triterpenoid	Flavonoid
<i>A. paniculata</i>	+	+	+++

Discussion

Many studies have stated that restricted control of hyperglycemic conditions over a while counters diabetic retinopathy progression, where HbA1c is a gold standard of glycemic control. Studies show a sustained association between the susceptibility to microvascular complications and glycemia. It means for every percentage point decrease in HbA1c (for example, 9% to 8%), there is a 35% lessening in the susceptibility to microvascular complications. Treatments with APE in this study significantly lowered blood glucose levels compared to untreated diabetic rats. HbA1c levels in diabetic rats that received APE treatment in this study showed reasonable glycemic control.

Various studies have shown that measuring retinal blood vessel diameter can present prognostic information about the possibility of microvascular complications of diabetes (17-19). Many researches stated that a wider retinal arteriolar diameter is related to the occurrence and development of diabetic retinopathy (19,20). This study has found greater dilation of retinal blood vessels in diabetic rats than in normal rats. The APE provided a better reduction in retinal blood vessel diameter than the untreated group.

TNF- α , a proinflammatory cytokine, affects the pathogenesis of diabetic retinopathy, and the risk of diabetic retinopathy has been related to polymorphisms of the TNF- α gene (21). TNF- α induces endothelial expression of adhesion molecules by activating nuclear factor- $\kappa\beta$ (NF- $\kappa\beta$). The NF- $\kappa\beta$ also increases the expression of other inflammatory mediators,

including cyclooxygenase-2 enzyme (COX-2) (21). Glycosylation products can also activate COX-2. This study showed that TNF- α levels in the retinas of diabetic rats were increased compared to normal rats.

Similarly, another study showed that retinal TNF- α levels were significantly greater in diabetic rats (22). Our study showed that administration of APE could reduce TNF- α levels in diabetic retinopathy rats. VEGF is a proinflammatory molecule that takes an essential part in neovascularization and vascular permeability, which causes retinal vascular damage (23). Various studies show that VEGF is increased in diabetic retinopathy conditions (23-25). This study also showed increased VEGF levels in rats with diabetic retinopathy. Furthermore, inhibition of VEGF activity limits the progress of vascular damage as in diabetic retinopathy. Our study demonstrated the potential of APE in reducing VEGF levels in rats with diabetic retinopathy.

In diabetes, antioxidant enzymes, which are responsible for cleansing free radicals and maintaining redox homeostasis, such as superoxide dismutase, catalase, and glutathione, are reduced in the retina (25). Furthermore, cells are supplemented with the intracellular GSH; which perhaps is the most crucial protection system that cells have (26). Intracellular GSH can execute as a scavenger of ROS and modulate the intracellular reduction-oxidation state. In diabetes, these intracellular antioxidants are lowered in the retina, and the metabolism enzymes are impaired. Our study found diabetic rats

exhibited subnormal levels of GSH and subnormal activity of antioxidant enzymes (SOD and CAT). These alterations in antioxidant parameters are consistent with previous research. The APE inhibited the decrease in SOD, CAT, and GSH. In conclusion, the doses of 100 and 200 mg/kg BW improved diabetic retinopathy in rats through hypoglycemic effects, antioxidant effects, and anti-inflammatory mechanisms.

References

1. Mansour SE, Browning DJ, Wong K, Flynn HW Jr, Bhavsar AR. The Evolving Treatment of Diabetic Retinopathy. *Clin Ophthalmol*. 2020;14:653-678.
2. Endris T, Worede A, Asmelash D. Prevalence of Diabetes Mellitus, Prediabetes and Its Associated Factors in Dessie Town, Northeast Ethiopia: A Community-Based Study. *Diabetes Metab Syndr Obes*. 2019;12:2799-2809.
3. Asmat U, Abad K, Ismail K. Diabetes mellitus and oxidative stress-A concise review. *Saudi Pharm J*. 2016;24(5):547-553.
4. Semeraro F, Morescalchi F, Cancarini A, Russo A, Rezzola S, Costagliola C. Diabetic retinopathy, a vascular and inflammatory disease: Therapeutic implications. *Diabetes Metab*. 2019;45(6):517-527.
5. Shaito A, Thuan DTB, Phu HT, Nguyen THD, Hasan H, Halabi S, Abdelhady S, Nasrallah GK, Eid AH, Pintus G. Herbal Medicine for Cardiovascular Diseases: Efficacy, Mechanisms, and Safety. *Front Pharmacol*. 2020;11:422.
6. Hidayat R, Wulandari P. Effects of *Andrographis paniculata* (Burm. F.) extract on diabetic nephropathy in rats. *Rep Biochem Mol Bio*. 2021;10(3):445-54.
7. Wediasari F, Nugroho GA, Fadhilah Z, Elya B, Setiawan H, Mozef T. Hypoglycemic effect of a combined *Andrographis paniculata* and *Caesalpinia sappan* extract in streptozocin-induced diabetic rats. *Adv Pharmacol Pharm Sci*. 2020;8856129.
8. Rocházková D, Bousová I, Wilhelmová N. Antioxidant and prooxidant properties of flavonoids. *Fitoterapia*. 2011;82(4):513-23.
9. Gheibi S, Kashfi K, Ghasemi A. A practical guide for induction of type-2 diabetes in rat: incorporating a high-fat diet and streptozotocin. *Biomed Pharmacother*. 2017;95:605-13.
10. Vucetic M, Jensen PK, Jansen EC. Diameter variations of retinal blood vessels during and after treatment with hyperbaric oxygen. *Br J Ophthalmol*. 2004;88:771-5.
11. Moron MS, Depierre JW, Mannervik B. Levels of glutathione, glutathione reductase and glutathione-S-transferase activities in lung and liver. *Biochem Biophys Acta*. 1979;582(1): 67-78.
12. Misra HP, Fridovich I. The oxidation of phenylhydrazine: superoxide and mechanism. *Biochemistry*. 1976;15:681-7.
13. Aebi H. Catalase. In: Bergmeyer HU, ed. *Methods in enzymatic analysis*. 1st ed. New York: Academic Press, 1974:673-7.
14. Lowry OH, Rosenbrough NJ, Farr AL, Randall RJ. Protein measurement with the Folin-phenol reagent. *J Biol Chem*. 1951;193:265-75.
15. Andrade-Cetto A, Rubalcaba Mares ML. Hypoglycemic effect of the *Rhizophora mangle* Cortex on STZ-NA induced diabetic rats. *Pharmacol Online*. 2012;3(3):1-5.
16. National Research Council (US) Institute for Laboratory Animal Research. *Guide for the Care and Use of Laboratory Animals*. Washington (DC): National Academies Press (US);1996.
17. Bek T. Diameter Changes of Retinal Vessels in Diabetic Retinopathy. *Curr Diab Rep*. 2017;17(10):82.
18. Papatheodorou K, Banach M, Bekiari E, Rizzo M, Edmonds M. Complications of

Acknowledgements

The authors would express their sincere gratitude to all staffs of Eureka Laboratory Research who had assisted the laboratory evaluation process of the samples.

Conflict of interest

The authors declare that there is no conflict of interest.

Diabetes 2017. J Diabetes Res. 2018;2018:3086167.

19. Klein R, Myers CE, Lee KE, Gangnon R, Klein BE. Changes in retinal vessel diameter and incidence and progression of diabetic retinopathy. Arch Ophthalmol. 2012;130(6):749-55.

20. Gui F, You Z, Fu S, Wu H, Zhang Y. Endothelial Dysfunction in Diabetic Retinopathy. Front Endocrinol (Lausanne). 2020;11:591.

21. Kaštelan S, Orešković I, Bišćan F, Kaštelan H, Gverović Antunica A. Inflammatory and angiogenic biomarkers in diabetic retinopathy. Biochem Med (Zagreb). 2020;30(3):030502.

22. Behl Y, Krothapalli P, Desta T, DiPiazza A, Roy S, Graves DT. Diabetes-enhanced tumor necrosis factor- α production promotes apoptosis and the loss of retinal microvascular cells in type 1 and type 2 models of diabetic retinopathy. Am J Pathol. 2008;172(5):1411-8.

23. Zafar MI, Mills K, Ye X, Blakely B, Min J, Kong W, et al. Association between the expression of vascular endothelial growth factors and metabolic syndrome or its components: a systematic review and meta-analysis. Diabetology Metab Syndrome. 2018;10:62.

24. Semadi IN. The role of VEGF and TNF- α on epithelialization of diabetic foot ulcers after hyperbaric oxygen therapy. Open Access Maced J Med Sci. 2019;7(19):3177-83.

25. Balbi ME, Tonn FS, Mendes AM, Borba HH, Wiens A, Fernandez-Llimos F, et al. Antioxidant effects of vitamins in type 2 diabetes: a meta-analysis of randomized controlled trials. Diabetol Metab Syndr. 2018;10:18.

26. Albert-Garay JS, Riesgo-Escovar JR, Salceda R. High glucose concentrations induce oxidative stress by inhibiting Nrf2 expression in rat Müller retinal cells *in vitro*. Sci Rep. 2022;12(1):1261.